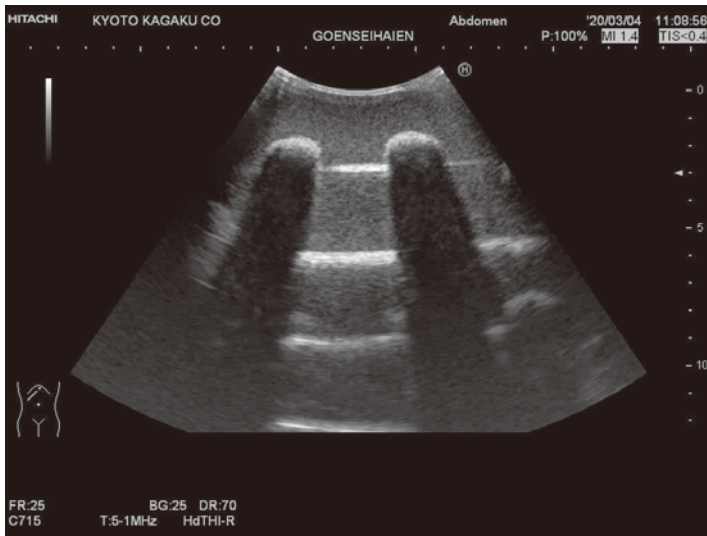
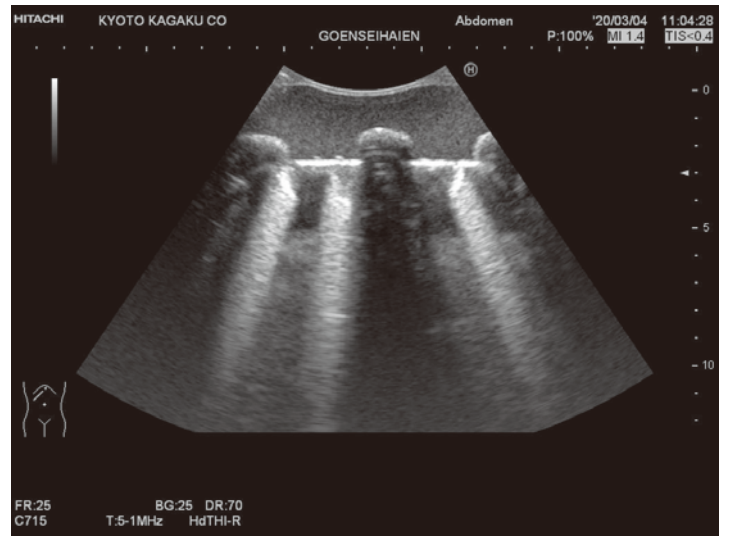


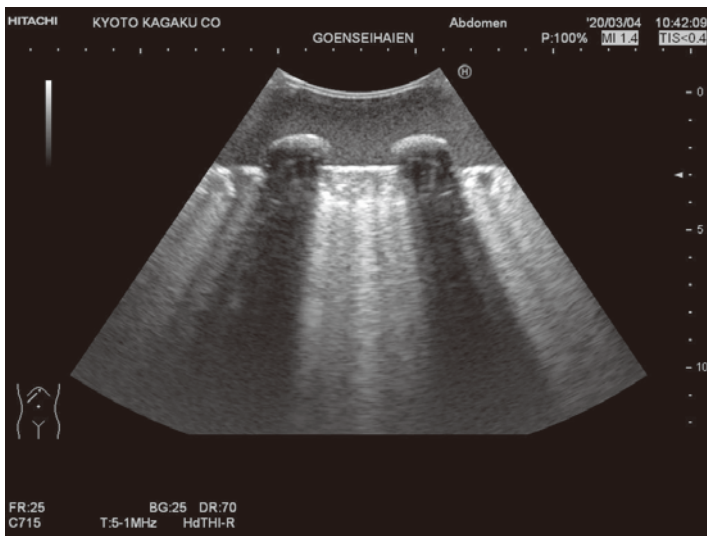
US-19 Lung Ultrasound Training Phantom ECHOLUNG



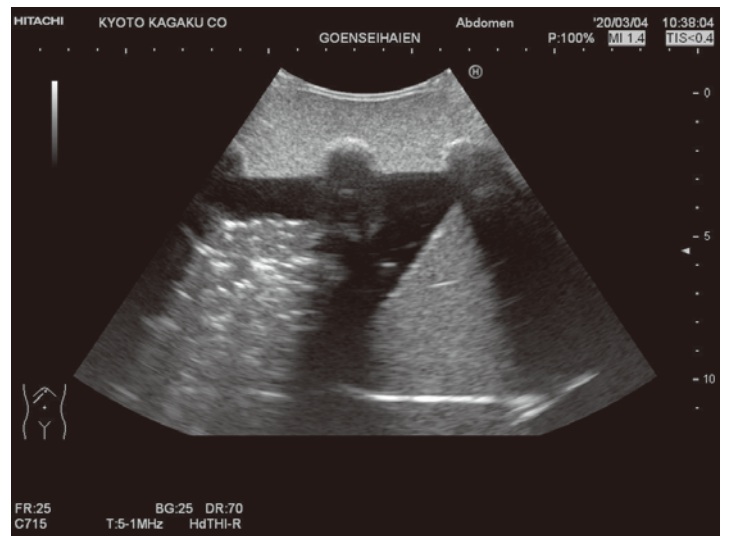
A-LINE



B-LINE



B-LINE (many)



Pneumonia and pleural effusion